

# Regenerative Injection Therapy for Osteoarthritis: Fundamental Concepts and Evidence-Based Review

Ariana Vora, MD, Joanne Borg-Stein, MD, Rosalyn T. Nguyen, MD

**Abstract:** Regenerative therapy involves the injection of a small volume of solution into multiple sites of painful ligament and tendon insertions (entheses) and adjacent joint spaces, with the goal of reducing pain and ostensibly promoting tissue repair and growth. Dextrose and platelet-rich plasma solutions have been shown to increase expression of growth factors in vivo and have shown promising clinical results in the treatment of tendinosis. In the treatment of osteoarthritis, small clinical trials and case series to date suggest safety, symptomatic improvement, and functional improvement at up to a year of follow-up; however, most of these studies are uncontrolled. Given the methodological limitations of clinical research on regenerative injections for osteoarthritis to date, this treatment should be considered only after execution of a comprehensive assessment and treatment plan, including optimization of biomechanics, weight loss, cardiovascular exercise, resistance training, and judicious use of more established topical, oral, and injectable medications.

*PM R 2012;4:S104-S109*

## INTRODUCTION

Regenerative therapies that use injectable agents such as dextrose prolotherapy and autologous platelet-rich plasma (PRP) are thought to promote new collagen deposition and remodeling in degenerative tissue by triggering the healing process (ie, inflammation, proliferation, and remodeling). The clinical applications of these therapies are being actively explored in a variety of disciplines including dentistry, plastic surgery, and musculoskeletal medicine and may have clinical application to the treatment of osteoarthritis (OA). In this article, we will review anatomic pain generators relevant to OA, introduce the theoretical basis of regenerative injection therapy, review basic science and clinical studies to date, describe the injection technique, and discuss the potential role of regenerative injection therapy in the treatment of OA.

## BACKGROUND AND DEFINITIONS

OA is the most common cause of joint pain [1]. In one survey, the prevalence of hip or knee pain on most days among adults ages 65-74 years was estimated at 40% [2]. OA is already a leading cause of disability among persons older than 60 years, and its prevalence is expected to increase dramatically in the next 30 years as the population ages [3]. OA is radiographically defined as intra-articular cartilage loss, bony hypertrophy, and capsular thickening [4]. In a case-control study comparing radiographic findings in persons with discordant pain between 2 knees, Neogi et al [5] demonstrated a strong correlation between radiographic joint space narrowing and frequent, severe knee pain. However, many persons have debilitating joint pain in the setting of minimal radiographic findings. Others have radiographic evidence of joint space narrowing in the absence of symptomatic or functional decline [6]. Large population studies have demonstrated that the radiographic grade of knee joint pathology does not consistently correlate with physical function [7].

The discordance between radiographic findings and clinical manifestations of defined OA invites deeper exploration of pain generators. For example, radiographs provide minimal information about meniscal and ligamentous tissue. Exploration of the neuroanatomic basis of pain and the biomechanics of joints is warranted for target- and tissue-specific

**A.V.** Department of Physical Medicine and Rehabilitation, Harvard Medical School, Spaulding Rehabilitation Hospital, Boston, MA. Address correspondence to: A.V., 65 Walnut Street, Suite 250, Wellesley MA 02481; e-mail: arianavora@gmail.com  
Disclosure: nothing to disclose

**J.B.-S.** Department of Physical Medicine and Rehabilitation, Harvard Medical School, Spaulding Rehabilitation Hospital, Boston, MA  
Disclosure: nothing to disclose

**R.T.N.** Department of Physical Medicine and Rehabilitation, Harvard Medical School, Spaulding Rehabilitation Hospital, Boston, MA  
Disclosure: nothing to disclose

Disclosure Key can be found on the Table of Contents and at [www.pmrjournal.org](http://www.pmrjournal.org)

treatment of OA; it also is a prerequisite for understanding the concepts behind regenerative injection therapies and their potential uses in osteoarthritic joints.

## NEUROANATOMIC BASIS OF PAIN IN OA

Human synovial joints are richly innervated. Histochemical studies reveal plentiful type IVa free nerve endings in the joint capsule, tendons, retinacula, fat pads, synovium, subchondral bone, and surrounding ligaments; these are the same nerve endings that detect pressure and mediate proprioception during joint movements [8]. Muscle and fascia are rich in substance P—positive free nerve endings, which are known to mediate nociception [9-11], as well as numerous mechanoreceptors, including stretch-sensitive muscle spindles, stretch- and contraction-sensitive Golgi receptors, and pressure-sensitive paciniform and Ruffini receptors [12].

Immunohistochemical studies in cadavers reveal that, in the setting of degenerative disease, substance P and calcitonin gene-related peptide are increasingly expressed in each of the aforementioned structures compared with healthy knees [13]. Further, anatomic studies reveal that the periosteum is richly innervated by myelinated and unmyelinated sensory fibers, including calcitonin gene-related peptide, and by sympathetic nerve fibers expressing tropomyosin receptor kinase A [14]. These fibers become progressively less dense in bone marrow and mineralized bone. Although hyaline cartilage itself is avascular and aneural [14], cartilage tears may be associated with local inflammation, which can trigger a nociceptive response in adjacent tissues.

## CONCEPT OF REGENERATIVE INJECTION THERAPY

The healing process comprises 3 phases: (1) inflammation, (2) proliferation, and (3) remodeling. The first phase includes recruitment of inflammatory mediators, hemostasis, and vasodilation. The second phase involves development of the extracellular matrix with granulation and epithelialization. The third phase involves production of collagen tissue and matrix maturation [15]. Regenerative therapy involves injection of a small volume of solution into multiple sites of painful ligament and tendon insertions (entheses) and adjacent joint spaces, with the goal of reducing pain and ostensibly promoting tissue repair and growth. The term “prolotherapy” implies proliferation of cells and is synonymous with regenerative injection therapy. A variety of injectates are designed for this purpose, such as sterile dextrose and autologous PRP. These substances, which are thought to trigger the healing cascade and thereby facilitate collagen deposition and remodeling, are both forms of regenerative injections or prolotherapy.

## REGENERATIVE AGENTS: EVIDENCE BASE

### Sterile Dextrose

The most common prolotherapy agent used in clinical practice is dextrose, with solutions ranging from 12.5%-25%. In vitro studies on human fibroblasts and chondrocytes demonstrate stimulation of growth factors with dextrose concentrations of 0.5% [16,17]. These growth factors include platelet-derived growth factor, transforming growth factor- $\beta$ , and insulin-like growth factor, which have been found in vitro to promote the expression of type 1 and 3 collagen in tenocytes [18]. In additional in vitro studies, human osteoarthritic synovial tissue exposed to glucosamine and glucose produced increased levels of hyaluronic acid production [19].

The clinical efficacy of dextrose prolotherapy in the treatment of OA has been investigated in several studies. Rabago et al [20] performed a double-blinded, prospective, randomized controlled trial of dextrose prolotherapy for symptomatic chronic knee OA using 3 interventions: dextrose prolotherapy, saline injections, and a home exercise program. Subjects assigned to the injection arms received injections at 1, 5, and 9 weeks, with as-needed repeat injection sessions at weeks 13 and 17. Extra- and intra-articular injections consisted of 15% and 25% dextrose, respectively, in the prolotherapy group. At each session, both periarticular and intra-articular injections were performed without image guidance. Outcome measures were the composite Western Ontario McMaster University Osteoarthritis Index (WOMAC) and the Knee Pain Scale. The groups receiving dextrose prolotherapy had significantly greater improvement in WOMAC scores at 52 weeks compared with the saline injection and exercise groups, exceeding the WOMAC minimal clinical important difference. Knee Pain Scale scores demonstrated similar improvement in the prolotherapy group compared with saline injection and exercise. No significant adverse effects were reported in any group, and patient satisfaction with the treatment was high in the prolotherapy group.

Reeves and Hassanein [21] performed a prospective, randomized, double-blind, placebo-controlled trial in persons with chronic knee OA with and without anterior cruciate ligament laxity. The treatment group received 3 bimonthly injections of 10% dextrose mixed with lidocaine and bacteriostatic water. The control group received the same solution without the dextrose. The groups treated with dextrose then received 3 additional bimonthly injections of 10% dextrose in an open-label fashion. The prolotherapy group demonstrated statistically and clinically significant improvements in Visual Analogue Score pain scores, swelling, buckling, and flexion range of motion compared with the control group at 6 months. At 12 months, the prolotherapy group demonstrated reduced anterior displacement difference as measured by the KT 100 arthrometer, but no control group was available for comparison of this measure. Interestingly, blinded radiographic readings at 0 and 12 months revealed

improvement in lateral patellofemoral cartilage thickness and distal femur width. Three-year follow up data also showed improvement in pain during walking, subjective reports of swelling, and range of motion in the group treated with dextrose [22].

In a study of patients with at least 6 months of thumb or finger pain and radiographic evidence of hand OA, Reeves and Hassanein [23] administered 3 bimonthly injections to the lateral and medial aspects of each affected joint with dextrose prolotherapy versus bacteriostatic water injections. Active flexion range of motion and pain with joint movement improved more in the dextrose group than in the control group. Pain at rest and with grip improved more in the dextrose group but was not statistically significant.

### Autologous PRP

PRP is a bioactive regenerative therapy that theoretically augments tissue healing through the natural healing cascade. Growth factors (insulin-like growth factor-1, transforming growth factor- $\beta$ , platelet-derived growth factor, vascular endothelial growth factor, and basic fibroblast growth factor) are released from the  $\alpha$  granules of platelets and induce chemotaxis, cell migration, angiogenesis, proliferation, differentiation, and matrix production, among a complex myriad of cellular functions that promote the healing cascade in tissue repair [24]. In a recent controlled laboratory study, the administration of PRP releasate was associated with a decrease in inflammatory cellular effects on osteoarthritic chondrocytes [25]. In cultured synovial fibroblast cells from 10 patients with OA, 72 hours of exposure to platelet-released growth factors significantly enhanced hyaluronic acid secretion compared with cells exposed to a platelet-poor preparation [26]. A subsequent study of fibroblast cultures from tendons exposed to platelet-rich growth factors duplicated this finding and also detected increased release of angiogenic growth factor compared with controls [27].

To formulate PRP, autologous whole blood is centrifuged to separate the platelet layer based on its specific gravity. This process results in a hyperphysiologic 3-8-fold concentrated solution of platelets, depending on the preparation. The addition of citrate binds ionized calcium and thus helps inhibit the clotting cascade. The addition of calcium chloride or thrombin activates the PRP and releases the growth factors. Preactivation with calcium chloride or thrombin can activate the PRP, leading to the release of 70% of the growth factors from the  $\alpha$  granules within 10 minutes and continuation of this release during the span of an hour [24].

In an uncontrolled case series, Kon et al [28] administered intra-articular PRP injections at 21-day intervals to 115 osteoarthritic knees, for a total of 3 sets of injections. International Knee Documentation Committee scores demonstrated statistically significant improvements at the 6-month follow-up compared with baseline levels, although some dimin-

ishment of scores was observed at the 12-month follow-up. Older patients with greater severity of OA, women, and patients with higher body mass index scores fared more poorly than their counterparts.

Subsequently, Kon et al studied PRP versus hyaluronic acid injections in 150 patients with knee OA and degenerative lesions in cartilage. Three PRP intra-articular injections were administered to 50 patients and compared with groups injected with high molecular weight versus low molecular weight hyaluronic acid. At the 6-month follow-up, the PRP group demonstrated better results with International Knee Documentation Committee scores, particularly among younger patients with cartilage lesions. However, none of the groups had significant improvements in cases of advanced OA [29].

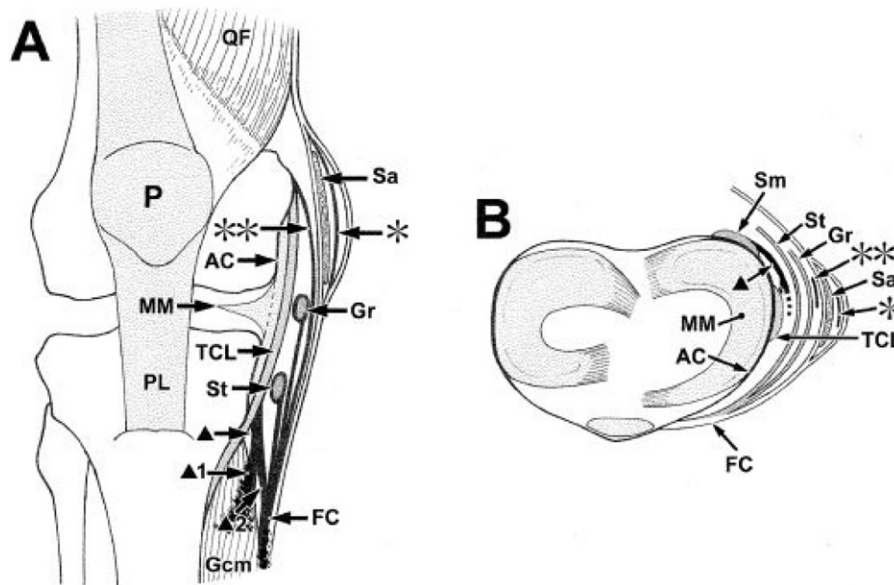
In a prospective, uncontrolled preliminary study, 3 PRP injections were administered at 4-week intervals to 14 patients with knee OA. Significant improvements were found in Knee Injury and Osteoarthritis Outcome scores, with relief of pain and symptoms [30]. In a second prospective, nonrandomized, longitudinal study, 261 patients with knee OA (Outerbridge grades I-IV) were given 3 intra-articular injections of platelet concentrate suspended in plasma from autologous blood at 2-week intervals. Participants had statistically significant improvements in pain and function at 6 months [31]. A third case series of PRP injections administered to 90 patients with knee OA revealed statistically significant improvements in pain and function at 6-month and 1-year follow-up. At the 2-year follow-up, patients had diminished gains compared with their results at the 1-year follow-up, although outcomes remained better than baseline levels. Younger patients and milder cases had better outcomes and longer-lasting results [32].

A recent Italian pilot study revealed positive results in their group of 27 patients with knee degenerative joint disease. The patients were treated with 3 weekly PRP injections and were found to have improvements in Numerical Rating Scale and WOMAC scores at 7 days after treatment, and they had further improvements at 6-month follow-up [33].

In addition to knee degenerative joint disease, hip OA also has been investigated. In a noncontrolled prospective study, 40 patients with severe hip OA were treated with 3 weekly ultrasound-guided PRP injections and were found to have statistically significant improvements in pain and function scores at 7 weeks and 6 months after treatment [34].

### Clinical Approach to Regenerative Injections

On the basis of clinical studies and the authors' experience, the following guidelines for regenerative injections for OA are proposed. Indications for regenerative injections include patients with clinical and radiographic evidence of OA, chronic periarticular joint sprain, or connective tissue laxity that



**Figure 1.** Schematic representation of the layered structures on the medial side of the knee joint. (A) Anterior view. (B) Superior view. AC = articular capsule; FC = fascia cruris; Gcm = medial head of gastrocnemius muscle; Gr = tendon of gracilis muscle and aponeurotic membrane from gracilis tendon; MM = medial meniscus; P = patella; PL = patellar ligament; QF = quadriceps femoris muscles; Sa = sartorius muscle; Sm = semimembranosus; St = tendon of semitendinosus muscle aponeurotic membrane from semitendinosus tendon; TCL = tibial collateral ligament; \* = superficial longitudinal fibrous bundle; \*\* = deep longitudinal fibrous bundle; ▲ = tendinous expansion of semimembranosus muscle; ▲1 = tendinous expansion of semimembranosus muscle fused with fascia of the medial head of gastrocnemius muscle; ▲2 = tendinous expansion of semimembranosus muscle fused with fascia cruris. Reprinted with permission from Mochizuki T, Akita K, Muneta T, et al. Pes anserinus: Layered supportive structure on the medial side of the knee. *Clin Anat* 2004;17:50-54.

impairs function across a joint, for whom standard treatments have been ineffective in improving pain or function. These treatments include but are not limited to biomechanical correction, exercise, oral and topical analgesics, physical therapy, weight loss, use of a cane, bracing, and previous corticosteroid or viscosupplementation injections [35].

No comparative studies of PRP versus dextrose prolotherapy have been published yet. If a large area is to be treated, dextrose solutions are preferred because more volume can be used; a standard large kit requires a 60-mL blood draw to yield 10 mL of PRP.

Contraindications for both PRP and dextrose prolotherapy include infection, immunocompromise, and inability to comply with guidelines for postprocedure instructions for activity and exercise. In the setting of anticoagulation, the injection can be considered if the International Normalized Ratio is less than 2.5 [36,37], but needle size is limited to 25 gauge, and spinal or noncompressible structures are not injected. In patients with prosthetic joints, intra-articular injections are not performed; however, extra-articular injections may be carefully considered for these patients, as long as the clinician recognizes the rare but catastrophic risk of prosthetic hardware infection. As discussed previously, milder degrees of OA have been associated with better outcomes compared with more severe cases of advanced OA or

cases with major anatomic structural deformity. If the patient's arthritis is sufficiently advanced that the patient would be better served by arthroplasty, regenerative injections are not offered.

Risks and benefits are thoroughly reviewed with patients. The risks and benefits are similar to any other intra-articular or periarticular injection and include infection, bleeding, bruising, peripheral nerve injury, allergy to local anesthetic, and temporary exacerbation of stiffness and soreness that may last up to 2-7 days. Potential benefits include reduced pain, increased joint stability, and improved function.

Through a comprehensive physical examination, in which the clinician considers both extra-articular and intra-articular structures, potential pain generators are identified. For example, in the knee, extra-articular pain generators might include the proximal tibia-fibular articulation, medial and lateral collateral ligamentous attachment sites or entheses, meniscotibial ligaments, pes anserine attachments, iliotibial band attachments, and insertions of the patellar and quadriceps tendons (Figure 1).

Simple analgesics such as acetaminophen can be used to manage postinjection soreness. Occasionally a patient will require a stronger analgesic, such as tramadol or hydrocodone. Nonsteroidal anti-inflammatory drugs are avoided during this time because they may impair the inflammatory

phase of healing. Immediately after PRP injections, regular daily activities and cross-training can be resumed as tolerated, and gentle range of motion is recommended. However, the authors advise patients to initially avoid impact loading of the injected area, such as running or jumping in the case of the lower extremities, or racquet sports in the case of the upper extremities. Initially, isometrics can be commenced (without range of motion) for about 2 weeks, and then the patient may advance to isotonic exercises with low-level resistance for about a week. At 6 weeks after the injection, if the patient has tolerated the exercise program, eccentric exercises can be added. Generally, at 8-10 weeks, full physical activity or sports retraining can take place.

Practices vary as to the frequency of treatment. For OA, dextrose prolotherapy often is performed in 4-week intervals, and PRP generally is performed with at least 2 months between treatments. Although most of the studies cited in this article report monthly treatments, no clinical evidence shows that less frequent treatment intervals would be less effective. Injections may be repeated until the patient reports 80% relief in symptoms or has reached a plateau clinically. If no improvement occurs after 2 injections, alternative therapies should be strongly considered. Outcome measures to measure clinical progress include pain scores, global percentage improvement, and functional gains, including both activities of daily living and recreational activities.

A full discussion of prolotherapy technique is beyond the scope of this review. The reader is referred to excellent texts [38-40] and comprehensive training programs through the Hackett-Hemwall-Hackett Foundation and the American Academy of Orthopedic Medicine. The authors strongly recommend that interested clinicians invest the time and resources in formal education and training to optimize patient selection, safe and effective technique, and outcomes. Prolotherapy traditionally has been taught through the use of precise physical examination findings and anatomic localization. Needling techniques include the standard injection technique (one needle pass through the tissue), peppering technique (several needle passes through the tissues), and layering or fanning techniques, but thus far no studies have evaluated superiority of one over another. The authors administer injections by using a comprehensive approach with treatment of painful or hypermobile intra-articular and extra-articular structures, including the joint capsule, ligaments, and tendons, treating all tender regional entheses points. The authors use musculoskeletal ultrasound guidance in addition to palpatory guidance with the aim of achieving more precise delivery of the injectate; however, the advantage of ultrasound guidance for regenerative injections has not been studied formally.

Currently neither prolotherapy nor PRP is covered by insurance. The cost differences vary from practice to practice, but generally, in light of the greater costs of the centrifuge equipment and individual sterile kits, PRP can be 2- to 4-fold

higher in cost. Logistic issues also must be considered when one uses PRP, which requires venipuncture, coordination among office staff, time spent processing the sample, and meticulous identification and matching of each sample to its corresponding patient; these considerations are not an issue with dextrose solutions, which can be prepared in minimal time for more than one patient.

## SUMMARY

OA pain is multifactorial; bony compression is not the only pain generator. Numerous regional intra-articular and extra-articular structures such as ligaments, tendons, and capsular tissue are richly innervated with nociceptive fibers. These structures should be considered when determining pain generators and tailoring a rehabilitation plan.

Regenerative injection treatments may stimulate collagen deposition in the ligaments, tendons, and capsule of osteoarthritic joints. Platelet-rich solutions have been found to enhance hyaluronic acid and angiogenic growth factor secretion in human synovial cells *in vitro*. Although small studies to date have suggested safety, pain relief, and functional improvements among patients with OA receiving regenerative injections, many of these studies are uncontrolled, and more clinical studies are needed.

Given the methodological limitations of clinical research on regenerative injections for OA to date, this treatment should only be considered after execution of a comprehensive physiatric assessment and treatment plan, including optimization of biomechanics, consideration of cane use, weight loss, cardiovascular exercise, resistance training, and judicious use of more established topical, oral, and injectable medications.

## REFERENCES

1. Woolf A, Pfleger B. Burden of major musculoskeletal conditions. *Bull World Health Organ* 2009;81:9:646-656.
2. Dawson J, Linsell L, Zondervan K, et al. Epidemiology of hip and knee pain and its impact on overall health status in older adults. *Rheumatology* 2004;43:497-504.
3. Peat G, McCarney R, Croft P. Knee pain and osteoarthritis in older adults: A review of community burden and current use of primary care. *Ann Rheum Dis* 2001;60:91-97.
4. Lawrence RC, Helmick CG, Arnett FC, et al. Estimates of the prevalence of arthritis and selected musculoskeletal disorders in the United States. *Arthritis Rheum* 1998;41:778-799.
5. Neogi T, Felson D, Niu J, et al. Association between radiographic features of knee osteoarthritis and pain: Result from two cohort studies. *BMJ* 2009;339:b2844.
6. Srikanth VK, Fryer JL, Zhai G, Winzeberg TM, Hosmer D, Jones G. A meta-analysis of sex differences, prevalence, incidence and severity of osteoarthritis. *Osteoarthritis Cartilage* 2005;13:769-781.
7. Sanghi D, Avasthi S, Mishra A, Singh A, Agarwal S, Srivastava RN. Is radiology a determinant of pain, stiffness, and functional disability in knee osteoarthritis? A cross-sectional study. *J Orthop Sci* 2011;16:719-725.

8. Biedert RM, Stauffer E, Freiderich NH. Occurrence of free nerve endings in the soft tissue of the knee joint. A histologic investigation. *Am J Sports Med* 1992;20:430-433.
9. Tesarz JJ, Hoheisel UU, Wiedenhoefer BB, Mense SS. Sensory innervation of the thoracolumbar fascia in rats and humans. *Neuroscience* 2011;194:302-308.
10. Gottschalk F, Kourosh S, Leveau B. The functional anatomy of tensor fascia lata and gluteus medius and minimus. *J Anat* 1989;166:179-189.
11. Flack NA, Nicholson HD, Woodley SJ. A review of the anatomy of the hip abductor muscles, gluteus medius, gluteus minimus, and tensor fascia lata (published online ahead of print November 22, 2011). *Clin Anat*. doi: 10.1002/ca.22004.
12. Yahia L, Rhalmi S, Newman N, Isler M. Sensory innervation of human thoracolumbar fascia. An immunohistochemical study. *Acta Orthop Scand* 1992;63:195-197.
13. Biedert RM, Sanchis-Alfonso V. Sources of anterior knee pain. *Clin Sports Med* 2002;21:335-347.
14. Dye SF, Vaupel GL, Dye CC. Conscious neurosensory mapping of the internal structures of the human knee without intraarticular anesthesia. *Am J Sports Med* 1998;26:773-777.
15. Reeves KD. Prolotherapy: Regenerative injection therapy. In: Waldman SD, ed. *Pain Management*. Philadelphia, PA: Saunders; 2007, 1106-1127.
16. Lam S, Van Der Geest RN, Verhagen NA, et al. Connective tissue growth factor and IGF-1 are produced by human renal fibroblasts and cooperate in the induction of collagen production by high glucose. *Diabetes* 2003;52:2975-2983.
17. Clarkson MR, Murphy M, Gupta S, et al. High glucose-altered gene expression in mesangial cells. *J Biol Chem* 2002;277:9707-9712.
18. Tang JB, Xu Y, Ding F, Wang XT. Tendon healing in vitro: Promotion of collagen gene expression by bFGF with NF-kB gene activation. *J Hand Surg* 2003;28:215-220.
19. Uitterlinden EJ, Koevet JL, Verkoelen CF, et al. Glucosamine increases hyaluronic acid production in human osteoarthritic synovium explants. *BMC Musculoskelet Disord* 2008;9:120.
20. Rabago D, Miller D, Zgierska A, et al. Dextrose prolotherapy for knee osteoarthritis: Results of a randomized controlled trial. Poster presented at: Osteoarthritis Research Society International World Congress on Osteoarthritis; September 15-17, 2011; San Diego, CA.
21. Reeves KD, Hassanein K. Randomized prospective double-blind placebo-controlled study of dextrose prolotherapy for knee osteoarthritis with or without ACL laxity. *Altern Ther Health Med* 2000;6:68-74, 77-80.
22. Reeves KD, Hassanein K. Long-term effects of dextrose prolotherapy for anterior cruciate ligament laxity. *Altern Ther Health Med* 2003;9:58-62.
23. Reeves KD, Hassanein K. Randomized, prospective, placebo-controlled double-blind study of dextrose prolotherapy for osteoarthritic thumb and finger (DIP, PIP, and Trapeziometacarpal) joints: Evidence of clinical efficacy. *J Altern Complement Med* 2000;6:311-320.
24. Nguyen RT, Borg-Stein J, McInnis K. Applications of platelet-rich plasma in musculoskeletal and sports medicine: An evidence-based approach. *PM R* 2011;3:226-250.
25. Van Buul GM, Koevoet WLM, Kops N, et al. Platelet-rich plasma releasate inhibits inflammatory processes in osteoarthritic chondrocytes. *Am J Sports Med* 2011;39:2362-2370.
26. Anitua E, Sanchez M, Nurden AT, et al. Platelet-released growth factor enhances the secretion of hyaluronic acid and induce hepatocyte growth factor production by synovial fibroblasts from arthritic patients. *Rheumatology* 2007;46:1769-1772.
27. Anitua E, Sanchez M, Zalduendo MM, et al. Fibroblastic response to treatment with different preparations rich in growth factors. *Cell Prolif* 2009;42:162-170.
28. Kon E, Buda R, Filardo G, et al. Platelet-rich plasma: Intra-articular knee injections produced favorable results on degenerative cartilage lesions. *Knee Surg Sports Traumatol Arthrosc* 2010;18:472-479.
29. Kon E, Mandelbaum D, Buda R, et al. Platelet-rich plasma intra-articular injection versus hyaluronic acid viscosupplementation as treatments for cartilage pathology: From early degeneration to osteoarthritis. *Arthroscopy* 2011;27:1490-1501.
30. Sampson S, Reed M, Silvers H, Meng M, Mandelbaum B. Injection of platelet-rich plasma in patients with primary and secondary knee osteoarthritis: A pilot study. *Am J Phys Med Rehabil* 2010;89:961-969.
31. Wang-Saegusa A, Cugat R, Ares O, et al. Infiltration of plasma rich in growth factors for osteoarthritis of the knee short-term effects on function and quality of life. *Arch Orthop Trauma Surg* 2011;131:311-317.
32. Filardo G, Kon E, Buda R, et al. Platelet-rich plasma intra-articular knee injections for the treatment of degenerative cartilage lesions and osteoarthritis. *Knee Surg Sports Traumatol Arthrosc* 2011;19:528-535.
33. Napolitano M, Matera S, Bossio M, et al. Autologous platelet gel for tissue regeneration in degenerative disorders of the knee. *Blood Transfus* 2011;Oct 25:1-6.
34. Sanchez M, Guadilla J, Fiz N, Andia I. Ultrasound-guided platelet-rich plasma injections for the treatment of osteoarthritis of the hip. *Rheumatology (Oxford)* 2012;51:144-150.
35. Reeves KD, Fullerton B, Topol G. Evidence-based regenerative injection therapy (prolotherapy) in sports medicine. In: Seidenberg PH, ed. *The Sports Medicine Resource Manual*. Philadelphia, PA: Saunders; 2008, 611-619.
36. Salvati G, Punzi L, Pianon M, et al. Frequency of the bleeding risk in patients receiving warfarin submitted to arthrocentesis of the knee. *Rheumatism* 2003;55:159-163.
37. Thumboo J, O'Duffy JD. Joint and soft tissue aspirations and injections in patients taking warfarin sodium. *Arthritis Rheum* 1998;41:736-739.
38. Reeves KD. Prolotherapy: Regenerative injection therapy. In: Waldman SD, ed. *Pain Management*. Philadelphia, PA: Saunders; 2007, 1106-1127.
39. Ravin TH, Cantieri MS, Pasquarello G. *Principles of Prolotherapy*. Denver, CO: American Academy of Musculoskeletal Medicine; 2008.
40. Rabago D, Patterson JJ, Baumgartner JJ. Prolotherapy: A CAM therapy or chronic musculoskeletal pain. In: Lennard TA, Vivian DG, Walkowski SD, Singla AK, eds. *Pain Procedures in Clinical Practice: Expert Consult*. 3rd ed. Philadelphia, PA: Saunders; 2011, 113-131.